

Transient epileptic amnesia: déjà vu heralding recovery of lost memories.

Fraser Milton¹, Christopher R. Butler², & Adam Z.J. Zeman³

¹ University of Exeter, Exeter, U.K.

² University of Oxford, Oxford, U.K.

³ Peninsula Medical School, University of Exeter, U.K.

Address for correspondence:

Fraser Milton
Washington Singer Laboratories,
Perry Road,
Exeter
U.K.
EX4 4QG
Tel: +44 1392 264650
Fax : +44 1392 724623
E-mail: f.n.milton@exeter.ac.uk

Word Count: 998

Key Words: transient epileptic amnesia; déjà vu; déjà vécu; remote memory.

Transient epileptic amnesia (TEA) is a form of temporal lobe epilepsy in which the main and sometimes only manifestation of the seizure is a period of amnesia, usually lasting less than 1-hour, during which other cognitive functions remain intact. Attacks are frequent, often occur on waking, and typically respond promptly to anticonvulsants. Patients with TEA often complain of persistent interictal remote memory impairment and accelerated forgetting of new information.[1]

Déjà vu is the disconcerting feeling that our current experience echoes some ill-defined past experience.[2] Déjà vu can be subdivided into a form related to the processing of familiarity, true déjà vu, and a form related to the processing of recollection, 'déjà vécu' ('already lived').[3] Many healthy people experience déjà vu occasionally, and it is sometimes a symptom of temporal lobe epilepsy.[2] However, in a recent study, no patients with TEA reported clear-cut déjà vu in relation to their amnesic seizures.[1] This could relate to the fact that déjà vu is more prevalent in younger people while TEA is a late onset disorder, or to the pathophysiology of amnesic seizures

We report a patient with TEA who experienced episodes of déjà vu approximately 5 years after cessation of his amnesic attacks. After these episodes he recovered salient autobiographical memories which had previously been forgotten.

Case Report

A 66 year old man presented with a history of TEA attacks from February 2002 to August 2002. Attacks started with an olfactory hallucination. His wife reported that this was followed by lip biting, grimacing, hand-wringing and an appearance of agitation. He would then turn pale and ask questions about the date or location repetitively. Attacks

typically lasted 30-60 minutes. Treatment with carbamazepine abolished the attacks promptly. Psychiatric assessment indicated a likely past episode of major depression at the time of his divorce 5 years prior to the onset of his seizures, but no evidence of affective illness at the time of assessment. EEG revealed no epileptiform abnormalities, whilst an MRI scan showed modest involutions over the parietal vertex and tiny foci of T2 high signal in peri-ventricular white matter, both within normal limits. Following cessation of the attacks, he reported a patchy, persistent autobiographical memory deficit extending back 30-40 years, together with topographical memory difficulties.

From mid-2007 to early 2008, he experienced around 6 episodes of déjà vu, lasting 3-10 seconds. Another episode occurred in September 2009. His description is suggestive, specifically, of déjà vécu.[2] Attacks were mildly unpleasant and included a slight pressure in the lateral frontal head regions. Shortly after episodes (5 minutes – 48 hours), memories for events that he had forgotten subsequent to his TEA attacks re-emerged. These were diverse in theme and emotional content, varying in age from approximately 6 months to 50 years prior to his attacks. He had no control over which memories were recovered. Since the episodes, his memory has remained stable. He could not specify the exact number of recovered memories, but stated the figure was considerably over 10. However, the patient still reports substantial gaps in his memory for autobiographical events.

We assessed his ability to retrieve contextual information for recovered memories by asking him to recall a recovered memory using the Autobiographical Interview.[4] The narrative was segmented into internal (information specific to the event) and external

(information extrinsic to the event) details. A rating assessing episodic richness, out of 21,[4] was included.

The patient recalled the wedding of his daughter, occurring approximately 8 years ago. His wife verified that the memory had been consistently inaccessible for approximately 6 years and that the information recovered was accurate. Several months prior to the recovery of the memory, the patient had read a copy of the speech he gave at the wedding reception but this had not cued any episodic recollection. 12 age-matched controls also recalled memories approximately 8 years old.

The patient scored marginally above controls for both the amount of internal and external details recalled (fig 1). Both patient and controls scored 20 on the rating measure. These results indicate that the patient had recovered a high level of contextual information for a previously lost memory.

Discussion

The cause of autobiographical memory loss in TEA is unclear.[1] Possible explanations include the mild hippocampal pathology apparent in patients with TEA and the propagation of clinical or sub-clinical epileptiform activity in the medial temporal lobes (MTL) to other regions of the ‘autobiographical memory network’ disrupting the memory trace. Neither theory predicts that lost memories would be recoverable. Previously, no patient with TEA has reported recovering inaccessible memories. In a case study, verbal and visual cues failed to trigger recollection, suggesting that the autobiographical memory loss in TEA is permanent.[5] The present case, however, indicates that, in some instances, the problem may be one of access rather than of the

permanent loss of memories. This could be due either to a pure impairment of retrieval or to compromised initial encoding due to sub-ictal electrical disturbance.

The close relationship between the recovery of lost memories and the preceding episodes of *déjà vu* suggests a link between the two phenomena. This is intriguing as *déjà vu* has not previously been associated with recovery of memories. This may reflect difficulty in verbalizing the elusive experience of *déjà vu*. However, the underlying mechanism may be similar to that by which electrical stimulation of the MTLs can induce *déjà vécu* together with reliving of personal memories from the distant or recent past.[6] It is unclear whether the episodes of *déjà vu* – or *vécu* - directly facilitated memory recovery, or represent a common outcome of a neural process which both triggered the experience of *déjà vu* and restored access to the ‘lost’ memories.

The sudden recovery of a group of memories is more typically observed in non-organic, ‘psychogenic’ amnesia than in ‘organic’ disorders such as TEA. However, commonalities between psychogenic and organic amnesia have been noted and there may be shared ground between the mechanism of the recovery of memories described above and the mechanisms of memory recovery in psychogenic amnesia.

Acknowledgements

We thank Chris Moulin for his comments, Great Western Research and Epilepsy Research UK.

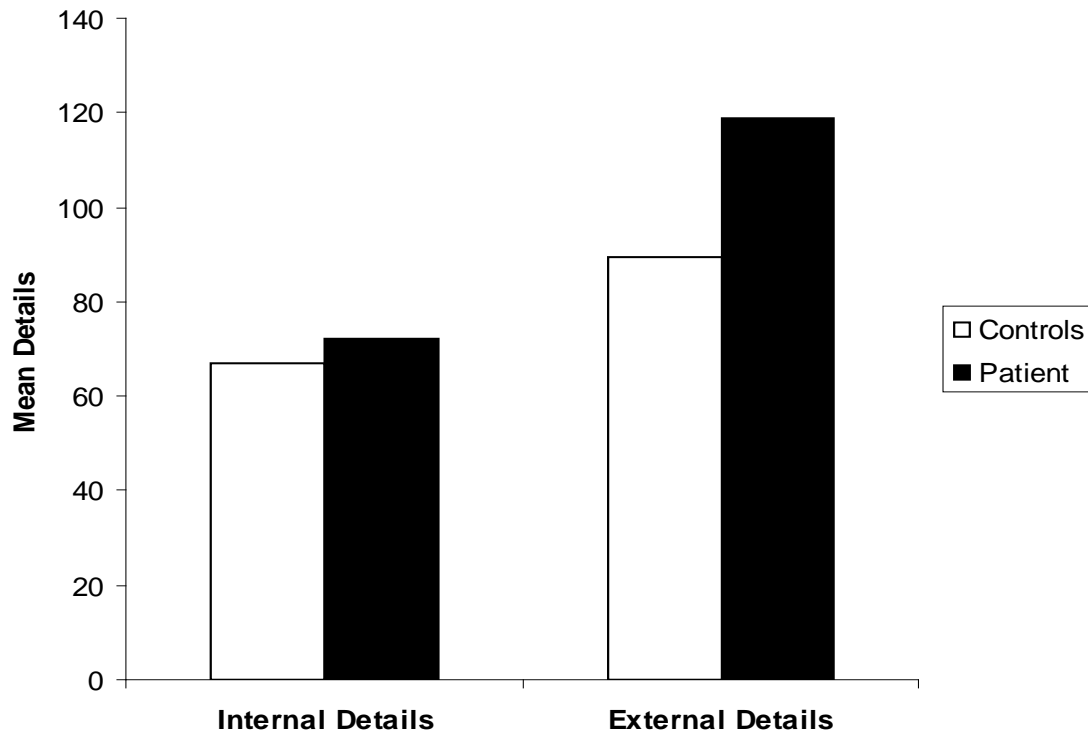


Figure 1. Mean number of internal and external details recalled.

The authors have no competing interests.

The Corresponding Author has the right to grant on behalf of all authors and does grant on behalf of all authors, an exclusive licence (or non-exclusive for government employees) on a worldwide basis to the BMJ Publishing Group Ltd and its Licensees to permit this article (if accepted) to be published in Journal of Neurology, Neurosurgery & Psychiatry and any other BMJ PGL products to exploit all subsidiary rights, as set out in our licence (<http://jnnp.bmjournals.com/ifora/licence.pdf>).

References

- ¹ **Butler CR**, Graham KS, Hodges JR, et al. The syndrome of transient epileptic amnesia. *Ann Neurol* 2007;61:587-598.
- ² **Moulin, CJA**, Conway, MA, Thompson, RG, et al. Disordered memory awareness: Recollective confabulation in two cases of persistent déjà vécu. *Neuropsychologia* 2005; 43: 1362-1378.
- ³ **Brown AS**. A review of the déjà vu experience. *Psychol Bull* 2003; 129: 394-413.
- ⁴ **Levine B**, Svoboda E, Hay, JF, et al. Aging and autobiographical memory: Dissociating episodic from semantic retrieval. *Psychol Aging* 2002;17:677-689.
- ⁵ **Manes F**, Hodges JR, Graham KS, et al. Focal autobiographical amnesia in association with transient epileptic amnesia. *Brain* 2001;124:499-509.
- ⁶ **Vignal, J-P**, Maillard, L, McGonigal, A, et al. The dreamy state: Hallucinations of autobiographic memory evoked by temporal lobe stimulations and seizures. *Brain* 2007; 130:88-99.